

# SURGICAL OPTIONS FOR CHRONIC GROIN PAIN IN FOOTBALL PLAYERS

– Written by John Garvey, Australia

## ABSTRACT

Athletic pubalgia (footballer's groin, groin disruption injury) is difficult to diagnose clinically and relies upon diagnostic imaging to detect a sports (occult) hernia. Sports hernia should be detected on ultrasound and the coexisting musculo-ligamentous injuries confirmed by clinical examination, ultrasound or MRI. Treatment is then initially commenced by physiotherapy, followed by surgery either, open mesh, suture or reconstruction, or laparoscopy: transabdominal pre-peritoneal (TAPP), totally extraperitoneal (TEP) or inguinal tenotomy. Success rates between 64 and 97% have been reported, but some of the numbers are small and the follow-up short, and outcome is undocumented. The open sutured repair 'tension-free tissue repair' is preferred to mesh implantation because of the increased risk of perioperative complications and the potential long-term

reproductive complications of mesh in young players.

## INTRODUCTION

'Chronic groin pain' in the athlete is caused by a pattern of injury known as 'athletic pubalgia, footballer's groin' or 'groin disruption injury' which consists of sports (occult) hernia, conjoint tendon tear, adductor tendinopathy, obturator nerve entrapment, osteitis pubis and labral tear of the hip joint. Sports hernia is prevalent in kicking sports such as football.

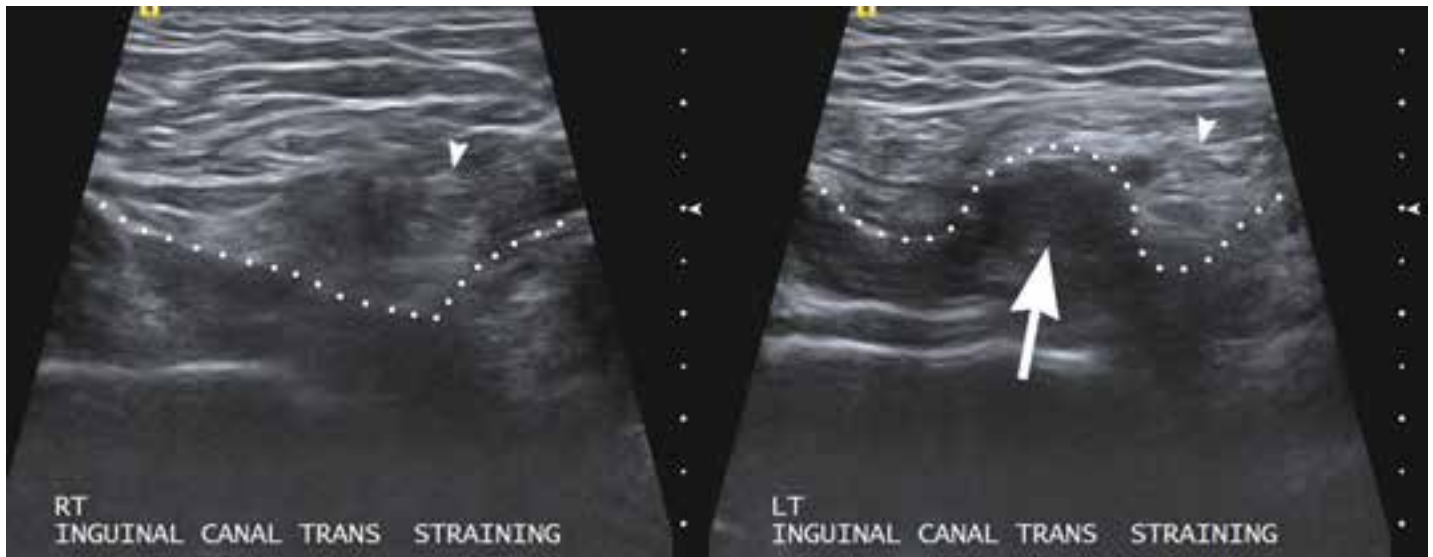
Sports hernia is a most controversial entity. It occurs through the torn fibres of the internal oblique muscle and transversus abdominis muscle insertion (conjoint tendon) medial to the inferior epigastric vessels in the inguinal (groin) canal of the lower abdomen. The presenting symptom is groin pain, discomfort, ache or lower abdominal pain but without a visible or

palpable hernia. Occasionally pain radiates to the testicle or perineum and radiation often occurs rostral to the supra-pubic region on the affected side.



***There are only  
2 randomised  
controlled trials  
available for study***





**Figure 1:** Ultrasound of incipient direct inguinal hernia. Comparison ultrasound images of the right and left inguinal canals have been obtained with the patient straining (performing a partial sit-up). Dotted lines indicate the posterior inguinal wall contours and arrowheads indicate the spermatic cords on each side. The posterior wall of straining right inguinal canal shows a normal straight contour, but the posterior wall of straining left inguinal canal shows a convex anterior bulge of incipient direct hernia (large arrow). This finding, when seen in an appropriate clinical setting with concomitant conjoint tendon lesion, is a 'sports hernia'. (Image and caption provided by J. R. Read).

#### CLINICAL EXAMINATION

The findings on clinical examination include a negative cough impulse, pain over the conjoint tendon insertion onto the pubic bone crest on the affected side during resisted sit-up 'crunch test' and a painful adductor 'hip adduction' Squeeze test.

#### IMAGING FINDINGS

The ultrasound finding of clinically occult (hidden) hernia is a helpful concept in the clinical setting where chronic groin pain exists, but swelling and a positive cough impulse are absent. Such a sports hernia is seen as a small direct convex bulge through the posterior wall of the inguinal canal which is evident on straining but reduces spontaneously when the abdominal wall is relaxed (Figure 1). Plain radiography shows cortical irregularity of the pubic bone (osteitis pubis) which can be bilateral, but tends to be worse on the affected side. The pelvis may also show widening of the sacro-iliac joint, limb length discrepancy (tilting of the pelvis to one side), pubic symphysis diastasis and pelvic instability on flamingo (contra-lateral leg-raise) views. Radionuclear bone scan or single photon emission computed tomography SPECT/CT

shows increased activity in the symphyseal joint and also around the conjoint tendon insertion and the adductor longus origin. CT scan imaging may indicate a small direct hernia and/or rectus muscle atrophy or asymmetry. MRI may show bone marrow oedema, secondary cleft sign, inguinal wall dynamics and some overview of most entities.

#### PREOPERATIVE MANAGEMENT

A trial period of 3 to 6 months of conservative management with physiotherapy is undertaken before determining if surgery is necessary. If a sports hernia involving muscle dehiscence of the internal oblique and transversus abdominis has occurred, these patients do not respond well to physiotherapy. The presence of a sports hernia is an indication for reconstructive surgery in a symptomatic player.

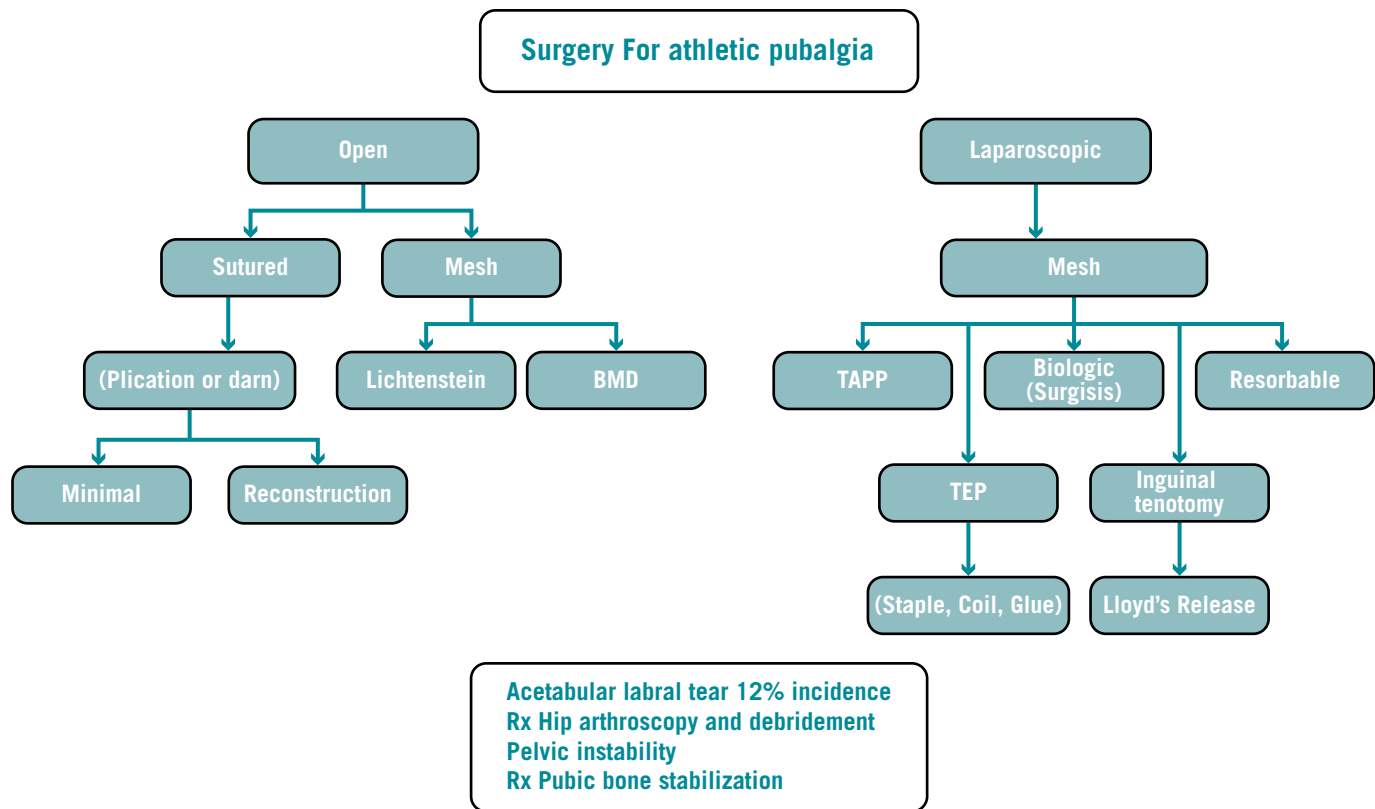
#### OPERATIVE FINDINGS

A small direct inguinal hernia or weakness in the medial inguinal fossa region is found, sometimes in association with a transverse split in the conjoint tendon as it inserts along the pubic crest.

The adductor longus tendon and its pubic insertion will usually be chronically inflamed and the obturator nerve lying deep to adductor longus may be entrapped in a fascial sheath on adductor brevis.

#### SURGICAL OPTIONS

Surgery for chronic athletic groin pain can be classified into open and laparoscopic techniques (Figure 2). The open technique can be a mesh repair (Lichtenstein) or a sutured repair (Shouldice). The suture repair can be 'minimal', that is plication of the Transversus abdominis and fascia transversalis in a double layer and excision of the genital branch of the genitofemoral nerve (Muschaweck), anterior pelvic floor repair (Meyers) or darn reconstruction (Gilmore). Release of the adductor longus insertion onto the pubic bone +/- release of the obturator nerve is often part of the groin reconstruction operation (Bradshaw). Laparoscopic repairs can be either TAPP, i.e. opening and closing peritoneum over a mesh repair, or TEP repair performed without breaching the peritoneum by entering the retro-rectus space, preserving the parietal peritoneum and inserting mesh fastened with helical tacks, staples or glue.



**Figure 2:** Schematic illustration for surgical management for athletes with groin disruption injury (sports hernia).

Lloyd's release involves inguinal ligament tenotomy, i.e. taking the inguinal ligament attachment off the pubic tubercle and reinforcing the posterior inguinal canal wall with mesh.

Symptomatic labral tear of the hip joint is treated by arthroscopy and debridement as a separate preceding operation by an orthopaedic specialist. Pubic bone stabilisation with plate or screws is a rarely used surgical option because of the risk of stress fractures of the pelvis, but has been found successful in Welsh international rugby players in association with a soft tissue reconstruction.

It is appropriate at this juncture to examine the objective clinical evidence for the role of surgery and there are only two randomised control trials available for study: one open inguinal repair and the other endoscopic.

#### Trial one

Ekstrand and Ringborg<sup>1</sup> provided the first randomised control trial that surgery could be used to treat athletic pubalgia when compared with no treatment or physiotherapy.

- 66 soccer players, average age 25, duration of symptoms 13 months.

- Incipient hernia on herniography ± positive test injection of local anaesthetic.
- Randomised groups:
  1. Modified Bassini repair and ilio-inguinal and ilio-hypogastric neurotomy.
  2. Physiotherapy three times per week, rest, non-steroidal anti-inflammatory drugs, strengthening lower abdominal muscles.
  3. Individual strength training exercises.
  4. Non-treated controls.
- Follow-up 3 and 6 months with visual analogue scale assessment – crossover to surgery offered.

Results showed that the individual training, physiotherapy and untreated control groups were unchanged at 6 months, whereas the operated group all had lower pain scores on coughing, sit-up, jogging, kicking and sprinting at 3 and 6 months.

Twenty three of the 45 patients from the non-surgical group crossed over to surgery. Surgery was found to be significantly effective in decreasing pain and improving function. The surgical candidates were cycling 2 to 3 weeks, running 4 to 5 weeks and training daily 6 to 8 weeks after surgery.

This study provided the first randomised control that hernia repair surgery could be effective in controlling chronic athletic groin pain.

#### Trial two

In a more recent paper Paajanen and co-workers in 2011<sup>2</sup>, provided the first objective clinical evidence that laparoscopic surgery can also be effective in patients with sports hernia (athletic pubalgia).

- Indication: chronic groin pain and 'suspected' sports hernia (blinded MRI).
- TEP repair vs 2/12 active physiotherapy + non-steroidal anti-inflammatory drugs + steroids.
- 60 patients (31 at national soccer level), 18 to 60 years old.
- Randomised control trial after 3 to 6 months of conservative treatment (but 28 other patients who did not want to lose time were not randomised).
- 67% unilateral, 33% bilateral.
- Exclusions: isolated adductor tendinopathy, avulsion fracture of pubic bone, pain referred from spinal cord, disorders hip joint or bursitis, mesh allergy, gynaecological, urological and digestive tract pathology.
- Polypropylene mesh: 10 × 15 cm and

fixed with 6 to 10 ProTack™ helical staples on to fascia transversalis ± tissue glue.

- Assessment: visual analogue scale 12 months after randomisation.
- Endpoint: full return to sport.
- Result: 90% success at 3 months vs 27% in the conservative group of whom 7 crossed over to the surgical group.

Interestingly, these workers implanted mesh bilaterally, even though the symptoms were unilateral, in order to prevent a later occurrence on the non-affected side. Diagnostic imaging was provided by (blinded) MRI, but at operation no macroscopic disruption of the posterior inguinal canal was found. Six of the 60 patients had adductor tendonitis and recovery was delayed when adductor tenotomy was performed in conjunction. Of great interest is that bone marrow oedema indicating osteitis pubis disappeared or improved after endoscopic surgery. These workers relied on surgery to cure the condition and had no specific postoperative physical therapy protocol to enhance players' rehabilitation.

Paajanen and co-workers concluded the following:

- Mesh supports the disrupted conjoint tendon better than anterior repair.
- Pressure is distributed evenly over this vulnerable area.
- Balloon dissection may assist neurolysis.
- Conjoint tendon defect, inguinal enthesopathy and osteitis pubis are manifestations of the same disease entity.
- Bone oedema, osteitis pubis, stress fracture and insertion tendonitis are all diverse symptoms of the same overuse injury which is disruption of the musculotendinous tissue attaching to the pubic bone.

So, these two studies demonstrated that open surgery and endoscopic repair are both effective in treating chronic groin pain.

#### OPEN INGUINAL HERNIA REPAIR WITHOUT MESH

Three workers: Drs OJA Gilmore (Nylon darn), Ulrike Muschaweck (minimal repair) and William Meyers (anterior pelvic floor repair) are the major exponents of open surgery.

OJA Gilmore<sup>3</sup>, whose experience relies on over 4,800 patients treated by surgery including a substantial number of English Premier League football players, believes that injury to the external oblique aponeurosis, conjoint tendon-pubic tubercle attachment and dehiscence between the conjoint tendon and the inguinal ligament cause posterior inguinal canal wall deficiency creating loss of inguinal canal integrity and lower abdominal or groin pain. He performed his first groin reconstruction in 1980. Gilmore believes the aetiology of the condition is muscle imbalance, with the hip flexors pulling the pelvis down and tilting the pelvis forward, causing weakness in the oblique muscles and a recurrent tear. His population was predominantly active young males and he regards the injury as rare over the age of 45 and rare in females. His operative findings describe split or shredding of the external oblique muscle and a dehiscence between the conjoint tendon and the inguinal ligament, and peripheral nerve entrapment in the external oblique aponeurosis. The sports players presenting to his clinic were football (56%), rugby union (10%), athletics (5%), racquet sports (4%), cricket (2%) and hockey (2%). His reconstruction operation aimed to restore normal anatomy to each layer. Through a 5 cm skin incision he repaired the transversus abdominis with a Vicryl® (absorbable) suture and performed a no. 1 nylon tension-free darn between the inguinal ligament and the internal oblique muscle. In his series, 40% of patients had adductor tendon tears and 18% had chronic severe adductor pain and required adductor tenotomy. The outcome of his operation was return to sport on average within 4 weeks (3 to 7 weeks range) with 97% success and 3% ipsilateral recurrence in professional footballers. Gilmore has observed coexisting pathology in the hip joint (femoro-acetabular impingement, labral tears) and an unstable pelvis in 6% of his subjects. He has performed bilateral reconstruction in association with pubic bone fusion in Welsh rugby union players, but this sidelines the players for 6 months and he has not reported any long-term follow-up in a small series.

Ulrike Muschaweck<sup>4</sup> (minimal repair) believes the injury is a medial displacement of the rectus abdominis muscle causing tension and pain on the pubic bone and

that the slide-bearing movement of the abdominal wall should be preserved. She prefers only 4 to 6 weeks of conservative treatment preoperatively to avoid chronic regional pain syndrome developing. Under local anaesthetic she makes a small incision in the fascia transversalis and performs a running overlapping suture in two layers that moves the rectus abdominis insertion laterally. The genitofemoral nerve is resected in 5 to 10% of cases and this nerve has been shown to be fibrotic on histological examination. Her reported results showed that 100% of her players get back to training by 10 days. She has seen no recurrent hernias in over 3,000 cases since 2003, and is performing follow-up on her patients to 5 years postoperatively.

In the United States, William Meyers<sup>5</sup> has been the major worker with high-performance athletes.

- Believes injury to be complex injury of flexion/adduction apparatus of lower abdomen and hip.
- Pain present for more than 3 months.
- Preoperative palpable hernia excluded from series.
- 157 new cases (138 with adductor pain, 88%).
- Operation: anterior pelvic floor repair (no specific details). Broad surgical reattachment of inferolateral edge of rectus abdominis muscle to pubis.
- Outcome: return to previous level of sports performance.
- 100% follow-up (including 45% physically examined 6 months after surgery).

Meyers' patients were imaged by MRI. Sixty patients had non-specific findings including rectus abdominis muscle tear, avulsion fracture of the pubic bone, bone marrow oedema and musculo-tendinous asymmetry. With a mean follow-up of 4 years so far, he noted 97% success at 6 months. Four patients developed contralateral symptoms by 4 years, and of 20 women evaluated only one underwent anterior pelvic floor repair. Meyers favours the name athletic pubalgia and believes laparoscopic surgery does not address the causes of pathology, and is unlikely to have a long-term successful outcome (but does not provide sufficient technical detail to reproduce his technique of anterior pelvic wall repair).

## Gilmore's experience relies on over 4,800 patients treated by surgery, including a substantial number of EPL football players

Branko Nesovic<sup>6</sup> from Serbia described a modified Bassini sutured repair for painful pubic symphysis syndrome in football players and presented his 20 years' experience in 1987.

- 1967 to 1987: 671 football players.
- 253 unilateral, 398 bilateral, no classical inguinal hernias detected at surgery.
- No recurrences.
- Provided the foundation for modern treatment of chronic groin pain in football players.

Nesovic pre-dated the modern era of hernia repair for groin disruption injury by 13 years and recent translation of his work into English highlights his extensive experience.

### OPEN MESH REPAIR

Less information about open mesh repair is available. Giampiero Campanelli<sup>7</sup> from Italy considers that rectus muscle hypertrophy pulling on tendons attached to the pubic bone and iliohypogastric nerve compression are the main operative findings. He reduces the bulge of the external oblique and releases the iliohypogastric and ilioinguinal nerves, and implants a lightweight mesh or biological mesh repair with fibrin glue. He believes that the muscles are strong and not weak, and therefore do not need a strong repair.

L Michael Brunt<sup>8</sup> from St Louis, Missouri, regards the injury as imbalance and stress across the pubic bone and tightness of the external oblique causing a defect in the posterior inguinal wall and peripheral nerve entrapment. He prefers a lightweight polypropylene mesh wrapped around the spermatic cord and sutured to the inguinal ligament. Because he has observed failures

with the laparoscopic repair, he favours this open Lichtenstein mesh approach and sometimes combines adductor tenotomy, which he believes increases the blood supply to the pubic bone. However, the use of mesh in healthy young males is problematical because of the potential complications of mesh shrinkage, contraction and migration, and chronic groin pain caused by mesh inguinodynia and nerve entrapment by mesh. There are also reproductive issues including ischaemic orchitis, dysejaculatory syndrome and obstructed azoospermia which are potential complications consequent upon the use of hernia mesh.

Mike H Scott<sup>9</sup> from Liverpool in England has significant experience in groin surgery and contends adductor tendonitis, lumbosacral pain and contralateral groin pain to be part of the Gilmore's groin/sports hernia/groin disruption injury syndrome. He considers those patients with atypical symptoms who do not do well after surgery have an acetabular labral tear of the hip joint on the affected side. He considers the pathogenesis to be unclear, but speculates that labral tears occur secondary to abnormal joint morphology, hip dysplasia, femoro-acetabular impingement or articular degenerative changes which can be diagnosed by FADIR (flexion, adduction, internal rotation) test and confirmed by MRI arthrogram.

He has also had experience with disruption to the conjoint tendon and has operated 1,200 cases between 1993 and 2009 with the following results after repair:

- Professional: 354 cases, 99% success at 6 weeks
- Semi-professional: 593 cases, 98% at 6 weeks

- Social: 253 cases, 68% success at 6 weeks
- 42 still in pain, 11 chronic groin pain

Sam Smedberg<sup>10</sup> from Sweden believes that injury is due to altered biomechanics of the musculo-skeleton due to strong leg muscles being unsupported by weak abdominal muscles. Overuse, endurance, excessive agility and uncoordinated balance cause loss of abdominal wall rotation and tension across the inguinal ligament causing disruption. His series comprises:

- 3 months – 10 year follow-up.
- Sutured Shouldice/endoscopic TEP repair.
- All returned to sport.
- Physical therapy can have role if high quality.
- Negative investigations – make sports hernia a diagnosis of exclusion.

In his series of open Shouldice repair or endoscopic TEP, all patients returned to their sport but most patients get better whatever surgery is done to them, and high quality physical therapy can have a role. *It is not clear how Smedberg accurately diagnosed sports hernia because he considers it a diagnosis of exclusion.*

### ADDUCTOR TENOTOMY

Coexistence of sports hernia with adductor tendinopathy has been reported in the literature. However, Ramon Cugat from Barcelona has performed isolated bilateral adductor longus and gracilis tenotomies in 107 patients with 99% success<sup>11</sup>. Ten patients had recurring groin pain but resolved on conservative treatment and 12 patients suffered "adherence rupture" but only one patient required repeat tenotomy. However, adductor tenotomy is seldom performed in isolation (3% in our initial

series from 1990-1999) and is usually combined with an open repair. Dojcinovic<sup>12</sup> and co-workers from Zagreb in 2012 performed a prospective study over 6 years on 99 patients and provided information on the incidence of adductor tendinopathy.

- 99 patients resistant to conservative treatment, 6 years follow-up.
- Sports hernia + double neurectomy (70/99); return to sport: 4 weeks (3-16)
- Adductor tendinosis/tenotomy (24/99); return to sport: 12 weeks (10-15)
- Isolated adductor tendinosis (5/99); return to sport: 13 weeks (12-16)

- Overall success rate for sports hernia repair was 97% who could continue at their previous level of activity.
- Adductor tendinosis occurs in 1/3 of all patients with chronic groin pain and must be treated by tenotomy.

This article provides a balanced overview of surgical options.

Bradshaw<sup>13</sup> has highlighted the issue of obturator nerve entrapment in 6% of 218 patients presenting between 2004 and 2006.

- Presentation: Medial thigh pain or paraesthesia.
- 32 cases of obturator neuropathy all

treated by surgical neurectomy.

- Electromyogram may show chronic denervation changes in adductor brevis.
- Compression results from fascial entrapment entering the thigh at adductor brevis.

He believes that obturator nerve release is indicated when obturator neuropathy is confirmed clinically and electrophysiologically, and is performed by releasing the fascia between the pectineus muscle and the adductor longus muscle and superficial to the adductor brevis muscle at the time of adductor tenotomy.



**Paajanen's first endoscopic TEP study in 2004 was a landmark article**



#### LAPAROSCOPIC REPAIR

Paajanen's first endoscopic TEP study in 2004<sup>14</sup> on minimally invasive treatment for sports hernia was a landmark article:

- 1996 to 2002: 41 male athletes; mean age 27.
- Criteria: history + pain on deep palpation at pubic tubercle and posterior inguinal wall and no other positive physical or imaging findings.
- Duration of symptoms: 9 months.
- 70% dominant leg, 10% bilateral.
- Sports: Football - 58%, Ice Hockey - 27%
- All failed conservative treatment (rest, steroids, physiotherapy)
- Four weeks follow-up, then long-term follow-up averaging 4 years by telephone contact
- Classical indirect inguinal hernia ruled out by palpation
- Classical medial direct inguinal hernia ruled out by laparoscopy
- Results
  - No macroscopic abnormality in 24/41
  - Conjoint tendon tear 10/41
  - Muscle asymmetry 7/41
  - Adductor magnus tenotomy 2/41
  - Success at 4 weeks 39/41(95%), without specific post-operative physical therapy.

Solvalor Morales-Conde<sup>15</sup> from Seville in Spain believes that the muscles of the lower extremity exert an opposite force to the abdominal muscles causing disruption of muscles or tendons creating a weak area in the groin (a "syndrome of muscle imbalance"), and uses a TEP endoscopic repair to reinforce the weakness with glue fixation or no fixation of lightweight mesh.

TAPP laparoscopic approach has been used by Ziprin<sup>16</sup> and colleagues in 17 patients (12 bilateral) who underwent a TAPP and interestingly were supervised by single physiotherapist. At 6 months, median return to sporting activity was 42 days, but there was one outcome failure in these 17 patients.

David Edelman<sup>17</sup> from Florida has promulgated the use of biological mesh for sports hernia and is experimenting with single port access for hernia repair.

- 120 patients: 48 right, 44 left, 28 bilateral.
- Average age 37.
- 93 male, 27 female.
- Retrospective since 2000.
- 4/52 post-operative rehabilitation.
- 6/12 follow-up.
- 94% success, 6% recurrence.
- Adverse effects: mild bladder "burning" (3) and mild post-operative groin pain (3).

*Biological mesh may have a role in those patients who have suffered mesh inguinodynia (neuralgia), but there could be*

*psycho-social barriers to have porcine small intestinal submucosa inserted into body cavities. The European Hernia Society has started registry for biological prostheses.*

A uniquely different approach to endoscopic surgery is taken by David Lloyd<sup>18</sup>, UK, with experience of football and rugby players. He likens the tension on the inguinal ligament to tennis elbow. At operation he finds swelling of the inguinal ligament and the pubic tubercle, conjoint tendinopathy and oedematous and attenuated lacunar ligament with holes above and below the inguinal ligament. He considers that the lacunar ligament is shrivelled and causes pain at the pubic bone and the fascia transversalis also looks abnormal. His surgical operation, 'Lloyds Release' releases the inguinal ligament and all attachments endoscopically from the pubic tubercle and performs a limited inguinal tenotomy and release of the pectineal fascia. He strips the ilio-pubic tract and peritoneum from the inguinal ligament and performs a TAPP repair with 12 × 15 cm mesh with fixation along the medial end of Cooper's ligament. He has found that 85% of patients had an improved severity of pain after the procedure and return to sport at one month, but has experienced an 8% failure rate.

An unbiased comparison between open and laparoscopic surgery was provided by Caudill et al in 2008.

- Criterion: return to pre-injury sport activity.
- Results are comparable between open surgery 93% (1/3 using mesh) and laparoscopic repair 96% success rate.
- Surgery is effective regardless of technique either open or laparoscopic.
- Recovery time: 17/52 for open, 6/52 for laparoscopic.
- Laparoscopic always requires insertion of mesh.
- Laparoscopic rehabilitation is faster, with quicker return to unrestricted sporting activity but cannot evaluate all associated lesions.
- Takes longer to learn (50 to 200 cases) and has more perioperative complications.
- But laparoscopic inguinal herniorrhaphy using prosthetic mesh can be contra-indication to endoscopic radical prostatectomy later in life.

## CONCLUSION

Using the criterion of return to pre-injury level of sport with no recurrence of injury (even allowing for high motivation to train and retain position within a team) up to 97% symptom relief and successful return to pre-injury level of sporting activity has been obtained with surgery. There is little evidence-based objective clinical data to guide decision making, and it is hoped that more randomised control trials with long-term outcome will be conducted to provide a valid comparison between physiotherapy and surgery. Until more randomised controls are forthcoming, physicians will be justifiably sceptical of an injury that necessitates no detectable objective clinical signs for diagnosis and an injury that can only be confirmed by surgery.

## References

1. Ekstrand J, Ringborg S. Surgery versus conservative treatment in soccer players with chronic groin pain: a prospective randomised study in soccer players. *Eur J Sports Traumatol Rel Res* 2001; 23:141-145.
2. Paaganen H, Brinck T, Hermunen H, Airo I. Laparoscopic surgery for chronic groin pain in athletes is more effective than non-operative treatment: a randomized clinical trial with magnetic resonance imaging of 60 patients with sportsman's hernia (athletic pubalgia). *Surgery* 2011; 150:99-107.
3. Gilmore OJA. Groin pain in the soccer athlete: fact, fiction and treatment. *Clin Sports Med* 1998; 17:787-793.
4. Muschaweck U, Berger L. Minimal Repair technique of sportsmen's groin: an innovative open-suture repair to treat chronic inguinal pain. *Hernia* 2010; 14:27-33.
5. Meyers WC, McKechnie A, Philippon MJ, Horner MA, Zoga AC, Devon ON. Experience with "sports hernia" spanning two decades. *Ann Surg* 2008; 248:656-665.
6. Nesovic B. (1987) *The painful symphysis syndrome in athletes and treatment possibilities*. Cited by Zarko Vuckovic. *Aspetar Sports Medicine Journal* 2012; 3:249-252
7. Campanelli G, Cavalli M, Canziani M, Ceriani F, Bertocchi V, Cattaneo C. Management of the sportsman's hernia. *Hernia* 2012; 16:S124-S125.
8. Brunt, LM. *Treatment of Sports Hernia*. American Hernia Society, *Hernia Repair* 2011, 26 March 2011 (cited in *Aspetar Sports Medicine Journal* 2012; 1:67-69).
9. Nicholson J, Scott M, Conjoint Tendon Disruption: Redefining and Recognising "Gilmore's groin", a review of 1,200 cases. *Hernia* 2012; 16:S143-S240.
10. Smedberg SG, Broome AE, Gullmo A, Roos H. Herniography in Athletes with Groin Pain. *Am J Surg* 1985; 149:378-382.
11. Cugat R, Llusa M, Golano P, Forcada P, Ruano D, Ballester J et al. Instructional course lecture no. 105: groin pain in soccer players. ISAKOS Congress 11-16 May 1997, Buenos Aires, Argentina. From <http://www.isakos.com/innovations/soccer.aspx>
12. Dojcinovic B, Sebecic B, Staresinic M, Jankovic S, Japjec M, Culjak V. Surgical Treatment of Chronic Groin Pain in Athletes. *Int Orthop*. 2012; 36:2361-2365.
13. Bradshaw C, McCrory P, Bell S, Brukner P. Obturator nerve entrapment: a cause of groin pain in athletes. *Am J Sports Med* 1997; 25:402-408.
14. Paajanen H, Syvahuoko I, Airo I. Totally extraperitoneal endoscopic (TEP) treatment of sportsman's hernia. *Surg Laparosc Endosc Percutan Tech*. 2004; 14:215-218
15. Morates-Conde S, Socas M, Barranco A. Sportsmen hernia: what do we know? *Hernia* 2010; 14:5-15.
16. Ziprin P, Prabhudesai SG, Abrahams, S, Chadwick SJ. Transabdominal preperitoneal laparoscopic approach for the treatment of sportsman's hernia. *Laparoscope Adv Surg Tech A*. 2008; 18:669-672.
17. Edelman D, Selesnick H. "Sports" Hernia: Treatment with Biologic Mesh (Surgisis): A Preliminary Study. *Surg Endosc* 2006; 20:971-973.
18. Lloyd DM, Sutton CD, Altafa A, Fareed K, Bloxham L, Spencer L, Garcea G. Laparoscopic inguinal ligament tenotomy and mesh reinforcement of the anterior abdominal wall: a new approach for the management of chronic groin pain. *Surg Laparosc Endosc Percut Tech* 2008; 18:363-368.
19. Caudill PH, Nyland JA, Smith CE, Yeresimides JG, Lach J. Sports hernias: a systematic literature review. *Br J Sports Med* 2008; 42:954-964.

John Garvey B.Sc. (Med), M.B., B.S.  
 General and Diagnostic Surgeon  
 Groin Pain Clinic  
 Sydney, Australia  
 Contact: [www.groinpainclinic.com.au](http://www.groinpainclinic.com.au)